

Original article

Randomized Comparison of Stent Strut Coverage Following Angiography- or Optical Coherence Tomography-guided Percutaneous Coronary Intervention



Jung-Sun Kim,^{a,b} Dong-Ho Shin,^{a,b} Byeong-Keuk Kim,^{a,b} Young-Guk Ko,^{a,b} Donghoon Choi,^{a,b} Yangsoo Jang,^{a,b,c} and Myeong-Ki Hong^{a,b,c,*}

^a Severance Cardiovascular Hospital, Yonsei University College of Medicine, Seoul, Korea

^b Cardiovascular Institute, Yonsei University College of Medicine, Seoul, Korea

^c Severance Biomedical Science Institute, Yonsei University College of Medicine, Seoul, Korea

Article history:

Received 7 May 2014

Accepted 3 July 2014

Available online 6 December 2014

Keywords:

Optical coherence tomography

Drug-eluting stent

Coronary disease

ABSTRACT

Introduction and objectives: The clinical benefits of optical coherence tomography-guided percutaneous coronary intervention are unclear. Therefore, in this study we sought to evaluate the impact of optical coherence tomography guidance on stent strut coverage following drug-eluting stent implantation.

Methods: A total of 101 patients in 105 lesions were randomly assigned to receive percutaneous coronary intervention under either optical coherence tomography guidance (n = 51 lesions of 50 patients) or angiography guidance (n = 54 lesions of 51 patients), and underwent a follow-up optical coherence tomography examination 6 months after zotarolimus-eluting stent implantation. The primary and secondary end points were the percentage of uncovered and malapposed struts, respectively, on 6-month follow-up optical coherence tomography.

Results: The percentage of uncovered struts was significantly lower in the optical coherence tomography-guided arm (1.60% [1.84]%, [median, 1.06%] vs 4.51% [5.43]%, [median, 2.38%]; P = .0004) at 6-month follow-up. The incidence of struts with $\geq 5.9\%$ uncovered struts was also significantly lower in the optical coherence tomography-guided arm (2 patients [3.9%] vs 14 patients [25.9%]; P = .002). In addition, the percentage of malapposed struts was significantly lower in the optical coherence tomography-guided arm (0.19% [0.51]%, [median, 0.0%] vs 0.98% [2.53]%, [median, 0.0%]; P = .027).

Conclusions: Optical coherence tomography-guided percutaneous coronary intervention significantly reduced the incidence of uncovered stent struts at 6 months compared to angiography-guided percutaneous coronary intervention. These findings suggest that optical coherence tomography-guided percutaneous coronary intervention has a beneficial effect on drug-eluting stent strut coverage.

© 2014 Sociedad Española de Cardiología. Published by Elsevier España, S.L.U. All rights reserved.

Estudio aleatorizado de comparación de la cobertura de los struts de los stents tras la intervención coronaria percutánea guiada por angiografía y la guiada por tomografía de coherencia óptica

RESUMEN

Introducción y objetivos: Los efectos beneficiosos clínicos de la intervención coronaria percutánea guiada por tomografía de coherencia óptica no están claros. Por ello en este estudio se intenta evaluar la influencia del uso de la guía de tomografía de coherencia óptica en la cobertura de los struts de los stents tras el implante de stents liberadores de fármacos.

Métodos: Se asignó aleatoriamente a 101 pacientes con 105 lesiones a tratamiento de intervención coronaria percutánea guiada por tomografía de coherencia óptica (n = 51 lesiones de 50 pacientes) o por angiografía (n = 54 lesiones de 51 pacientes), y se les realizó un examen de seguimiento por tomografía de coherencia óptica a los 6 meses del implante de un stent liberador de zotarolimus. Los objetivos principal y secundario eran el porcentaje de struts no cubiertos y con mala aposición, respectivamente, en el seguimiento realizado a los 6 meses con tomografía de coherencia óptica.

Resultados: El porcentaje de struts no cubiertos fue significativamente inferior en el grupo de tomografía de coherencia óptica (el 1,60 \pm 1,84% [mediana, 1,06%] frente al 4,51 \pm 5,43% [mediana, 2,38%]; p = 0,0004)

Palabras clave:

Tomografía de coherencia óptica

Stent liberador de fármaco

Enfermedad coronaria

SEE RELATED ARTICLE:

<http://dx.doi.org/10.1016/j.rec.2014.09.017>, Rev Esp Cardiol. 2015;68:175–8.

* Corresponding author: Division of Cardiology, Severance Cardiovascular Hospital, Yonsei University College of Medicine, 250 Seongsanno, Seodaemun-gu, Seoul 120-752, Korea.

E-mail address: mkhong61@yuhs.ac (M.-K. Hong).

<http://dx.doi.org/10.1016/j.rec.2014.07.025>

1885-5857/© 2014 Sociedad Española de Cardiología. Published by Elsevier España, S.L.U. All rights reserved.

en el seguimiento realizado a los 6 meses. La incidencia de *stents* con $\geq 5,9\%$ de *struts* no cubiertos fue también significativamente inferior en el grupo de tomografía de coherencia óptica (2 pacientes [3,9%] frente a 14 [25,9%]; $p = 0,002$). El porcentaje de *struts* con mala aposición fue significativamente inferior en el grupo de tomografía de coherencia óptica (el $0,19 \pm 0,51\%$ [mediana, 0,0%] frente al $0,98 \pm 2,53\%$ [mediana, 0,0%]; $p = 0,027$).

Conclusiones: La intervención coronaria percutánea guiada por tomografía de coherencia óptica redujo significativamente la incidencia de *struts* de *stents* no cubiertos a los 6 meses, en comparación con la intervención coronaria percutánea guiada por angiografía. Estos resultados indican que la intervención coronaria percutánea guiada por tomografía de coherencia óptica tiene un efecto beneficioso en cobertura de los *struts* de los *stents* liberadores de fármacos.

© 2014 Sociedad Española de Cardiología. Publicado por Elsevier España, S.L.U. Todos los derechos reservados.

Abbreviations

DES: drug-eluting stent
IVUS: intravascular ultrasound
OCT: optical coherence tomography
PCI: percutaneous coronary intervention

INTRODUCTION

Delayed vascular and endothelial healing is associated with stent thrombosis following implantation of a drug-eluting stent (DES) in pathologic studies.^{1,2} High-resolution assessment of stent struts *in vivo*³ using optical coherence tomography (OCT) shows that uncovered stent struts are associated with late stent thrombosis after DES implantation.^{4,5} Previous studies show that larger-sized acute stent malapposition may be responsible for persistent stent malapposition and the development of uncovered stent struts during follow-up.^{6,7} Compared to intravascular ultrasound (IVUS), high-resolution OCT results in superior apposition of stent struts to the vessel wall. To determine if this improved strut apposition was associated with improved stent strut coverage, we performed a prospective randomized study comparing strut coverage during follow-up after either OCT-guided or angiography-guided DES implantation.

METHODS

Study Population

This study was a prospective, open-label, randomized, single-center trial, registered at ClinicalTrials.gov (NCT01869842). A total of 117 patients with 124 coronary lesions were enrolled between December 2011 and December 2012 and randomly assigned to receive either OCT- or angiography-guided implantation of a zotarolimus-eluting stent (Endeavor ResoluteTM, Medtronic CardioVascular; Santa Rosa, California, United States). Inclusion criteria were: *a*) age ≥ 20 years old and significant coronary *de novo* lesion(s) ($\geq 70\%$ diameter stenosis on visual estimation), and *b*) a native coronary artery with a reference vessel diameter between 2.5 mm and 4.0 mm that could be covered by a single stent. Exclusion criteria were the following: *a*) refusal to participate; *b*) participation in other study protocols; *c*) lesions with significant left main disease or chronic total occlusion; *d*) lesions in a grafted vessel, thrombosis, or bifurcation lesions requiring 2 stents; *e*) an ejection fraction $\leq 30\%$; *f*) allergy to either antiplatelet agents or the contrast dye; *g*) known renal failure with baseline creatinine level ≥ 2.0 mg/dL, or end-stage renal disease; *h*) life expectancy < 1 year; *i*) prior DES treatment of a different vessel within 3 months; *j*) presence of an overlapping stent or long stent (> 30 mm); *k*) lesion calcification visible on angiography, and *l*)

current pregnancy, or women of childbearing potential. During the same study period, percutaneous coronary intervention (PCI) was performed in 1300 patients. Of these patients, 1183 were excluded. Twenty-five patients refused participation, 405 were participating in other study protocols, and 753 met the remaining criteria, as follows: left main disease in 75, chronic total occlusion in 55, graft vessel disease in 23, totally occluded thrombotic lesion in 125, bifurcation lesions requiring 2 stents in 45, ejection fraction $< 30\%$ in 48, chronic renal failure (creatinine level ≥ 2 mg/dL) in 92, long lesion (> 30 mm stent) or overlapping stents in 135, and anatomy not suitable for OCT procedure in 155. This randomized study was approved by the institutional review board of our institute and written consent was obtained from all enrolled patients.

Randomization and Study Procedures

All study participants fulfilling the enrollment criteria of this study were randomly assigned in a 1:1 ratio by an interactive web-based response system to receive OCT- or angiography-guided PCI. To preserve a balance between the 2 strategies, randomization was stratified according to the presence of diabetes mellitus, acute coronary syndrome, and the estimated length and diameter of the prospective DES implant. All patients received at least 75 mg of acetylsalicylic acid and a loading dose of 300 mg of clopidogrel at least 12 hours pre-PCI. Unfractionated heparin was administered as needed to maintain the activated clotting time of > 250 seconds. All PCI procedures were performed according to current standard techniques. In the OCT-guided arm, adjuvant postdilatation was performed at operator discretion based on OCT findings. In the angiography-guided arm, stent optimization including adjuvant postdilatation was based on a visual estimation of angiographic findings and procedural success was defined as $\leq 20\%$ residual stenosis after stent placement by visual estimation. Postprocedure treatment included a 12-month prescription of dual antiplatelet therapy with 100 mg acetylsalicylic acid and 75 mg clopidogrel daily.

Quantitative Coronary Angiography Analysis

Quantitative coronary angiography analysis was performed before and after stent implantation, and at 6-month follow-up using an off-line quantitative coronary angiographic system (CASS system, Pie Medical Instruments; Maastricht, The Netherlands) in an independent core laboratory (Cardiovascular Research Center, Seoul, Korea). Reference vessel and minimal luminal diameters were obtained by comparison to the guidance catheter from diastolic frames in a single, matched view showing the smallest minimal luminal diameter: post-PCI and follow-up angiograms were evaluated in the same projection. Acute gain was defined as the difference between preprocedure and postprocedure minimal luminal diameter. Late loss was defined

as the change in minimal luminal diameter between postprocedure and follow-up.

Optical Coherence Tomography Imaging and Analysis

At postprocedure and 6-month follow-up after PCI, OCT imaging of the target lesion was performed using a frequency-domain OCT system (C7-XR OCT imaging system, LightLab Imaging, Inc., St. Jude Medical; St. Paul, Minnesota, United States). In this study, OCT cross-sectional images were recorded at 100 fps while a catheter was pulled back at 20 mm/s within the stationary imaging sheath. All OCT images were analyzed blind by independent analysts at the core laboratory (Cardiovascular Research Center).

Cross-sectional OCT images were analyzed at 1 mm intervals. Stent and luminal cross-sectional areas were measured, and neointimal hyperplasia cross-sectional area was assessed as the difference between the stent and luminal cross-sectional areas. Mean or median values are reported in this study. The neointimal hyperplasia thickness was measured as the distance between the endoluminal surface of the neointima and the strut, and an uncovered strut was defined as having a neointimal hyperplasia thickness of 0 μm .⁸ A malapposed strut of zotarolimus-eluting stent was defined as detachment from the vessel wall by $\geq 110 \mu\text{m}$ (stent strut thickness 91 μm + abluminal polymer thickness 6 μm , considering blooming artifact). The proportions of uncovered or malapposed struts were identified from OCT cross-sections, and are expressed as a percentage of total struts visible in the survey. In addition, uncovered struts associated with major adverse cardiovascular events, including cardiovascular death, nonfatal myocardial infarction, and stent thrombosis, were subclassified based on the degree of strut coverage as described (favorable coverage, < 5.9% uncovered; unfavorable coverage, $\geq 5.9\%$ uncovered).⁹ Malapposed struts, which included any amount of malapposition, were further classified into persistent, resolved, or late stent malapposition, according to the change in malapposition visible in matching frames between postprocedure and follow-up OCT.¹⁰ Intrastent thrombi were defined as irregular masses protruding into the lumen, > 250 μm at the thickest point.¹¹

Study End Points and Clinical Follow-up

Clinical follow-up was performed at 1, 3, 6, and 12 months after PCI; angiographic and OCT follow-up was performed at 6 months. The primary end point was the percentage of uncovered struts in the 6-month follow-up OCT assessments. Secondary end points were: a) the presence of malapposed struts in the 6-month follow-up OCT; b) the occurrence of major adverse cardiac events at 12 months, defined as a composite of cardiac death, nonfatal myocardial infarction, or patients requiring target lesion revascularization, and c) stent thrombosis at 12 months, as defined by the Academic Research Consortium.¹²

Statistical Analysis

This study was designed to compare the 6-month follow-up strut coverage of OCT-guided PCI vs angiography-guided PCI. We hypothesized that the improved stent apposition associated with high-resolution OCT guidance might reduce the incidence of uncovered struts by 50% at the 6-month follow-up OCT, compared to angiography guidance. Assuming 4.8% (4.3%) incidence of uncovered struts at 6-month follow-up, based on our prior studies of zotarolimus-eluting stents at 3 months (6.2%) and 9 months (3.4%),^{13,14} a sample size of 51 patients for each arm would provide

80% power and a 5% alpha error rate. Taking into account a 10% loss rate and exclusion due to poor OCT image quality, 114 patients were needed for the study. Statistical analysis was performed with the Statistical Analysis System software (SAS; 9.1.3., SAS Institute; North Carolina, United States). Categorical data are presented as numbers and percentages, and were compared with chi-square statistics or Fisher exact test. Continuous data are presented as the mean (standard deviation) (median) and compared with the Student *t* test. If the distributions were skewed, a nonparametric test was used. Hierarchical linear modeling was applied for the clustering problem. Specifically, data for lesions, cross-sections, and struts were modeled for each patient as a random effect variable. With this modeling, the clustering and correlation problems could be controlled. In case of clustered variables with nonnormal distributions, we integrated the results of hierarchical linear modeling with nonparametric analysis. A value of $P < .05$ denoted statistical significance.

RESULTS

A total of 117 patients with 124 coronary lesions were randomly assigned into treatment groups receiving PCI with either OCT guidance ($n = 58$) or angiography guidance ($n = 59$). Postprocedure OCT was performed on 56 patients (59 lesions) in the OCT-guided arm and revealed that the OCT catheter had not passed through the lesions in 2 patients (2 lesions). In the OCT-guided arm, 50 patients (51 lesions) received follow-up at 6 months, compared to 51 patients (54 lesions) in the angiography-guided arm; 10 patients refused follow-up coronary angiography; 1 patient had in-stent restenosis with tight narrowing; 1 patient had subacute stent thrombosis; the OCT catheter was not passed through the stented lesions in 2 patients. The overall study diagram is shown in [Figure 1](#). Baseline patient characteristics were comparable between the 2 arms ([Table 1](#)). Adjuvant postdilatation was more frequent in the OCT-guided arm (51.0% vs 27.8%, $P = .03$). However, additional treatment was not performed in cases of OCT-detected small-sized thrombus or tissue prolapse and minor edge dissection. In total, 101 patients (105 lesions) were evaluated by OCT at follow-up, and there were no serious complications during the procedure. Serial OCT findings are summarized in [Table 2](#).

In the OCT-guided arm, the incidences of malapposed struts and lesions with any malapposed strut were 3.3% and 66.1% (39 of 59), respectively, immediately after the index procedure. The percentage of uncovered struts at 6 months was significantly lower using OCT-guidance (1.60% [1.84%] [median, 1.06%] vs 4.51% [5.43%] [median, 2.38%] using angiography; $P = .0004$). [Figure 2](#) shows representative examples of follow-up angiography and OCT between OCT- and angiography-guided PCI. Angiography cannot detect strut coverage. Moreover, stent strut coverage was more favorable in OCT guidance irrespective of clinical presentation or the presence of diabetes mellitus ([Figure 3](#)). At the 6-month follow-up OCT, the incidence of unfavorable strut coverage ($\geq 5.9\%$ of uncovered struts) was significantly lower in the OCT-guided arm [2 patients (3.9%) vs 14 patients (25.9%), $P = .002$; [Figure 4](#)], as was the percentage of malapposed struts (0.19% [0.51%] [median, 0.0%] vs 0.98% [2.53%] [median, 0.0%]; $P = .027$).

One-year clinical follow-up was completed in all enrolled patients. There were no significant differences in major adverse cardiac events (2 of 58 [3.4%] in the OCT arm vs 3 of 59 [5.1%] in the angiography arm). Stent thrombosis occurred in a single patient in the angiography arm 2 days after implantation; target lesion revascularization was performed in 4 patients (2 OCT-guided patients and 2 angiography-guided patients). Of these 5 patients, 6-month follow-up OCT evaluation was not performed on the patient with stent thrombosis, and we were unable to pass the OCT

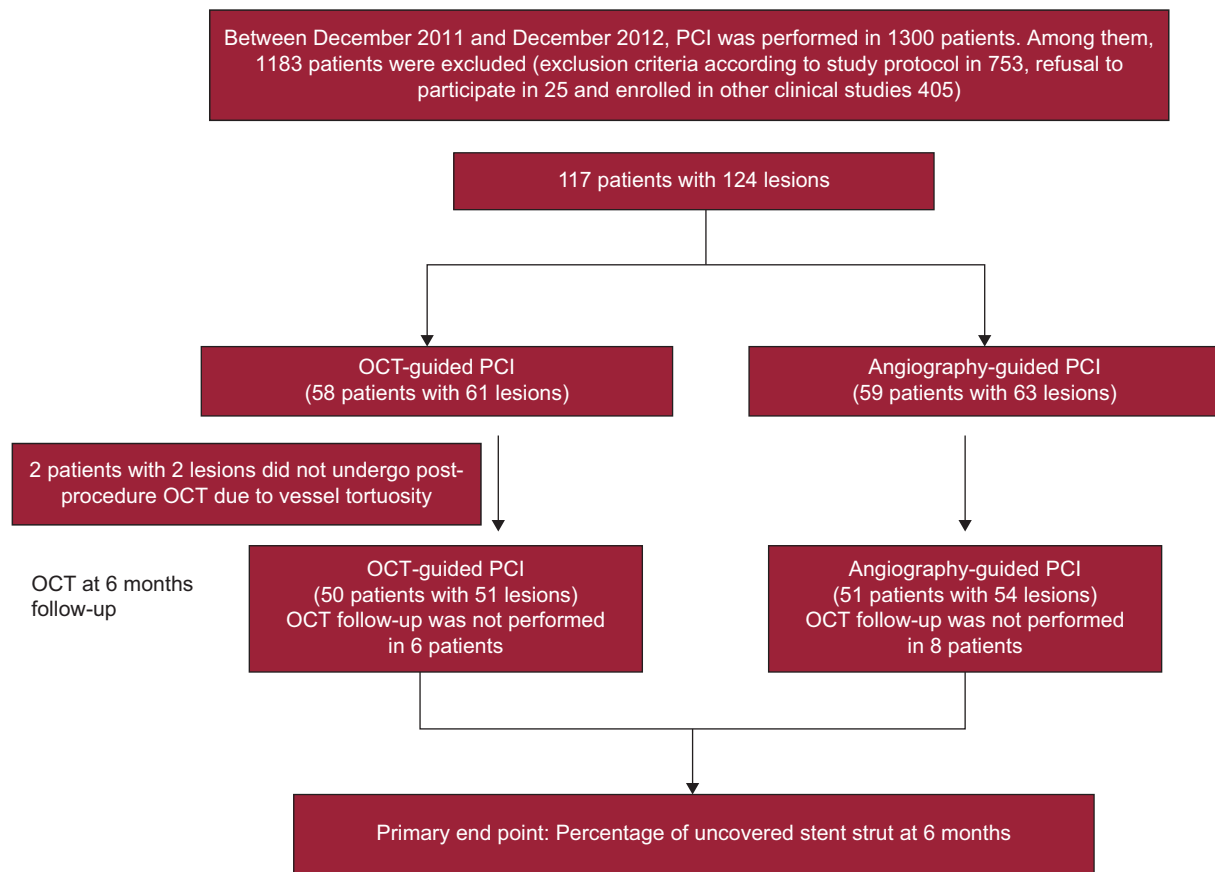


Figure 1. Study flow diagram. OCT, optical coherence tomography; PCI, percutaneous coronary intervention.

catheter through the tightest lesion in 1 of the OCT-guided patients who underwent target lesion revascularization.

DISCUSSION

Our randomized, prospective comparison of OCT- and angiography-guided PCI demonstrated that OCT-guidance was associated with significantly improved outcomes with respect to strut coverage and stent apposition at 6 months. In addition, the incidence of stents with unfavorable strut coverage ($\geq 5.9\%$ of uncovered struts) was significantly lower following OCT guidance compared to angiography guidance. Adjuvant postdilation was more frequently performed in the OCT-guided arm. These findings suggest that OCT-guided PCI had a beneficial effect on stent strut coverage.

Although angiography guidance is widely performed during PCI, this method has only limited capability for accurately evaluating vessel size, lesion length, stent expansion, malapposition, and complications after stent implantation.¹⁵ The IVUS was introduced to overcome these limitations of angiography guidance, and may be useful for complex coronary interventions, such as those involving left main, bifurcation, and diffuse long lesions.^{16–19} The resolution of IVUS is 100 μm in the axial plane, and 200–250 μm in the lateral plane, whereas the resolution of OCT is ~ 10 -fold higher (10–15 μm), which is sufficient to visualize individual stent struts and more detailed vascular structures. Consistent with this, neointimal coverage was visible on 99.9% of stent struts using OCT, vs only 25.8% using IVUS, since a considerable proportion of the neointima is $< 100 \mu\text{m}$, which is

thinner than the resolution of IVUS.²⁰ Despite this, few prospective studies have assessed the potential benefits of OCT-guided PCI.

Based on analysis of autopsy samples, incomplete endothelialization and neointimal coverage over DES struts are proposed to be significant pathologic risk factors for stent thrombosis,^{1,2} and OCT and angioscopic studies identified a significant correlation between uncovered struts and subclinical intracoronary thrombus.^{21,22} Furthermore, the results of a recent retrospective case-control study using OCT suggest that the length of uncovered stent struts is a significant risk factor for late stent thrombosis.⁵ In addition, recent studies from our group tried to identify the cut-off value of uncovered struts that best predicted adverse clinical outcomes (cardiovascular death, myocardial infarction, and stent thrombosis) after DES implantation. During the median of 851 [interquartile range, 488–1215] days after OCT examination, clinical events occurred in 6 of 489 patients (4 definite stent thrombosis and 2 sudden cardiac death); the study proposed that the best cut-off value of uncovered struts percentage for predicting cardiovascular events was 5.9%, with a sensitivity of 83.3% and specificity of 70.3%.⁹ Consequently, identifying techniques to improve the extent of strut coverage may translate into a decreased incidence of adverse cardiovascular events and intracoronary thrombus during follow-up. Since acute stent malapposition is associated with delayed strut coverage of sirolimus-eluting stents at 10 months,⁶ minimizing acute stent malapposition may reduce the rate of uncovered struts later.

In the present study, we have tested this hypothesis using OCT guidance to optimize stent apposition and assessing stent strut coverage at 6 months. Our main finding was that the percentage of uncovered struts was significantly lower in the OCT-guided arm

Table 1
Patient Characteristics

	OCT-guided PCI	Angiography-guided PCI	P
Patients, No.	50	51	
Age, mean (SD), y	58.8 (10.8)	61.6 (9.7)	.27
Male	39 (78.0)	37 (72.5)	.52
Hypertension	27 (54.0)	25 (49.0)	.62
Diabetes mellitus,	16 (32.0)	16 (31.4)	.95
Dyslipidemia	33 (66.0)	37 (72.5)	.48
Current smoking	16 (32.0)	15 (29.4)	.78
Prior myocardial infarction	3 (6.0)	8 (2.0)	.36
LVEF, mean (SD), %	64.2 (7.4)	63.6 (8.6)	.56
Clinical presentation			.94
<i>Stable angina</i>	31 (62.0)	31 (60.8)	
<i>Acute coronary syndrome</i>	19 (38.0)	20 (39.2)	
Target long lesions, No.	51	54	
<i>Coronary arteries</i>			
Left anterior descending artery	31 (60.8)	30 (55.6)	
Left circumflex artery	11 (21.6)	14 (25.9)	.84
Right coronary artery	9 (17.6)	10 (18.5)	
<i>B2 or C lesion</i>	48 (94.1)	52 (96.3)	.67
<i>Lesion length, mean (SD), mm</i>	16.1 (3.9)	15.8 (4.6)	.71
<i>Stent diameter, mean (SD), mm</i>	3.2 (0.5)	3.2 (0.4)	.93
<i>Stent length, mean (SD), mm</i>	18.0 (3.9)	17.6 (4.3)	.80
<i>Adjuvant postdilatation</i>	26 (51.0%)	15 (27.8%)	.03
<i>Adjuvant balloon size, mean (SD), mm</i>	3.35 (0.54)	3.33 (0.40)	.93
<i>Maximal inflation pressure, mean (SD), atm</i>	16.1 (3.0)	16.3 (3.8)	.85
<i>Reference vessel diameter, mean (SD), mm</i>	3.08 (0.52)	3.23 (0.57)	.16
<i>Balloon-to-artery ratio, mean (SD)</i>	1.10 (0.14)	1.03 (0.11)	.01
<i>Minimal lumen diameter, mm</i>			
Preintervention, mean (SD)	0.96 (0.45)	0.92 (0.44)	.66
Postintervention, mean (SD)	2.99 (0.47)	3.01 (0.48)	.85
6 month follow-up, mean (SD)	2.68 (0.52)	2.78 (0.44)	.33
<i>Acute gain, mean (SD), mm</i>	2.03 (0.53)	2.09 (0.63)	.62
<i>Late loss, mean (SD), mm</i>	0.31 (0.33)	0.24 (0.26)	.21

LVEF, left ventricular ejection fraction; OCT, optical coherence tomography. PCI, percutaneous coronary intervention; SD, standard deviation. Unless otherwise indicated, data are expressed as no. (%) or mean (standard deviation).

than in angiography-guided arm (1.60 [1.84]% vs 4.51 [5.43]%; $P = .0004$) at the 6-month follow-up. The proportion of uncovered struts and neointimal hyperplasia thickness following angiography guidance in the present study were comparable to our previous studies^{13,14} using zotarolimus-eluting stents (4.51% at 6 months [6.2% at 3 months and 3.3% at 9 months] and 96 μm at 6 months [74 μm at 3 months and 139 μm at 9 months], respectively). These observations suggested that OCT guidance could decrease the incidence of uncovered struts with less variability at 6 months after stent implantation. In addition, the incidence of unfavorable strut coverage was significantly lower in the OCT-guided arm (2 patients [3.9%] vs 14 patients [25.9%]; $P = .002$) and the extent of stent strut coverage was less variable in OCT-guided arm. These findings suggest that the adoption of OCT-guidance during PCI will ensure consistently favorable strut coverage. The OCT-guided strategy may have a role to shorten the duration of dual antiplatelet therapy after DES-treated lesions with favorable strut coverage.²³ Our findings are in accordance with a retrospective finding that OCT-guided PCI is associated with improved clinical outcomes at 12 months, due to reduced cardiac deaths and myocardial infarctions.²⁴ Optical coherence

tomography guidance is also suggested to provide benefits in other clinical settings when identifying neoatherosclerosis as the cause of stent restenosis or stent thrombosis.^{25,26} As is seen with IVUS guidance, OCT provides information during PCI on stent underexpansion and stent malapposition, which enabled adjuvant balloon dilation to be performed more frequently in the OCT-guided arm in this study (51.0% vs 27.8%; $P = .03$).

Study Limitations

Our study has some limitations. First, we cannot compare the incidence of acute stent malapposition associated with OCT and angiography guidance because postprocedure OCT examination was only performed in the OCT-guided arm. In addition, adjuvant postdilatation for malapposition or stent expansion was not defined as a specific criterion but was performed at operator discretion in this trial. We need to investigate optimal OCT criteria to improve stent strut coverage, apposition, and clinical outcomes during follow-up. Second, our results are only informative for simple lesions, since patients with complex coronary lesions—diffuse long

Table 2
Optical Coherence Tomography Assessment of Stents at Immediate Postprocedure and 6-month Follow-up

	OCT-guided PCI (postprocedure)	OCT-guided PCI (follow-up)	Angiography-guided PCI (follow-up)	P ^a
Lesions analyzed, No.	59 (96.7)	51 (83.6)	54 (85.7)	
Time to follow-up OCT, mean (SD), days	–	202 (36)	200 (31)	.601
Total number of analyzable struts, No.	12 547	10 824	11 201	–
Mean NIH thickness, mean (SD), μm	–	102.7 (67.3) [77.6]	96.0 (108.8) [69.1]	.793
Percentage of uncovered strut, mean (SD), %	–	1.60 (1.84) [1.06]	4.51 (5.43) [2.38]	.0004
Percentage of malapposed strut, mean (SD), %	3.30 (4.40)	0.19 (0.51) [0.00]	0.98 (2.53) [0.00]	.027
Both of malapposed and uncovered strut, mean (SD), %	–	0.07 (0.29) [0.00]	0.40 (1.33) [0.00]	.082
Total number of cross sections, No.	1041	912	944	
Mean stent CSA, mean (SD), mm^2	7.95 (2.42)	8.01 (2.27)	7.84 (2.54)	.780
Mean lumen CSA, mean (SD), mm^2	7.71 (2.32)	7.17 (2.27)	7.17 (2.38)	.947
Minimal stent area, mean (SD), mm^2	6.66 (2.18)	6.57 (1.96)	6.61 (2.27)	.915
Mean NIH CSA, mean (SD), mm^2	–	0.84 (0.61) [0.57]	0.67 (0.53) [0.51]	.155
Mean percent NIH CSA, mean (SD), %	–	11.10 (8.60) [7.80]	8.70 (5.40) [7.52]	.103
Cross-sections with any uncovered strut, mean (SD), %	–	14.00 (15.00) [9.09]	28.00 (25.30) [21.30]	< .001
Cross-sections with uncovered strut > 0.3, mean (SD), %	–	0.1 (0.1) [0.0]	2.3 (5.5) [0.0]	.007
Cross-sections with any malapposed strut, mean (SD), %	14.5 (15.3)	1.8 (4.8) [0.0]	6.9 (16.0) [0.0]	.026
Maximal length of malapposed struts, mean (SD), mm	0.73 (1.07) [0.20]	0.10 (0.35) [0.00]	0.53 (2.25) [0.00]	.17
Maximal extrastent lumen CSA, mean (SD), mm^2	0.79 (0.67) [0.59]	0.36 (0.52) [0.19]	0.46 (0.59) [0.25]	.35
Maximal malapposed distance, mean (SD), μm	183 (14) [160]	43 (97) [0]	128 (224) [0]	.01
Presence of intrastent thrombi	–	0 (0)	0 (0)	1.000
Stent malapposition	35 (68.6)	9 (17.6)	18 (33.3)	.07
Persistent	–	9	–	
Resolved	–	26	–	
Late-acquired	–	0	–	

CSA, cross-sectional area; NIH, neointimal hyperplasia; OCT, optical coherence tomography; PCI, percutaneous coronary intervention. Unless otherwise indicated, data are expressed as No. (%), mean (standard deviation) or [median].

^aP-value between optical coherence tomography-guided percutaneous coronary intervention vs angiography-guided percutaneous coronary intervention at 6 months follow-up.

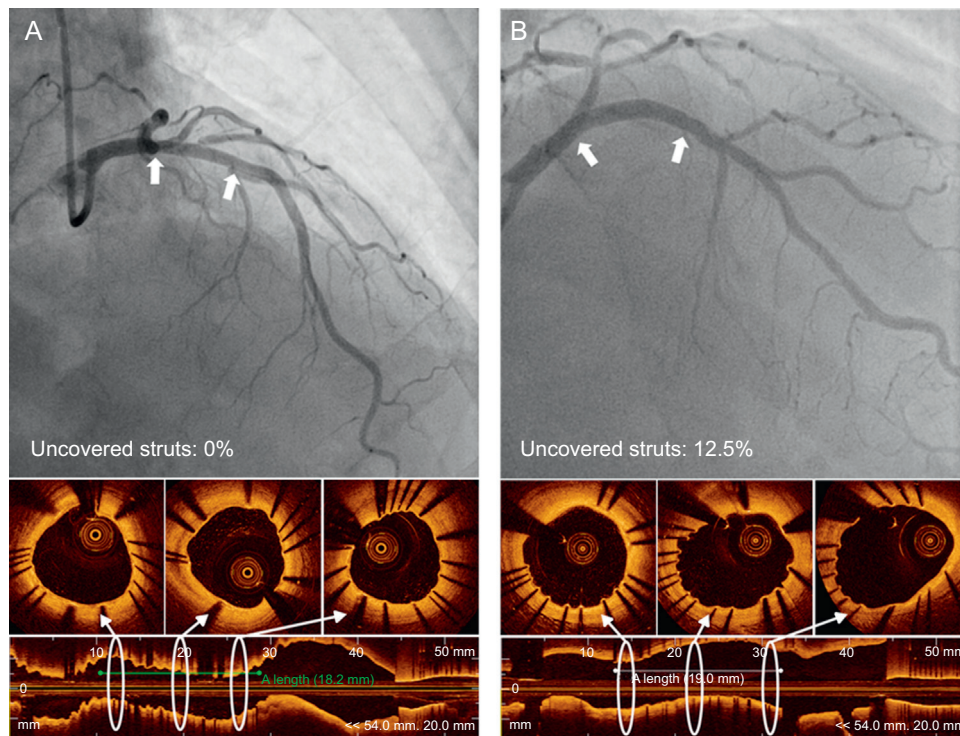


Figure 2. Representative angiography and optical coherence tomography images at 6-month follow-up in optical coherence tomography guidance (A) and angiography guidance (B).

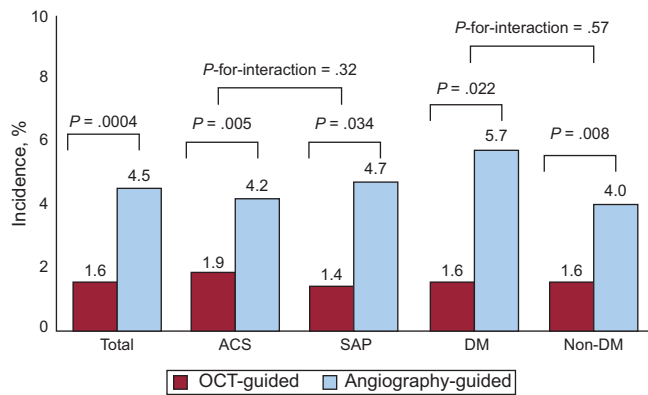


Figure 3. The incidence of uncovered struts at 6 months overall and relative to patient characteristics. ACS, acute coronary syndrome; DM, diabetes mellitus; OCT, optical coherence tomography; SAP, stable angina pectoris.

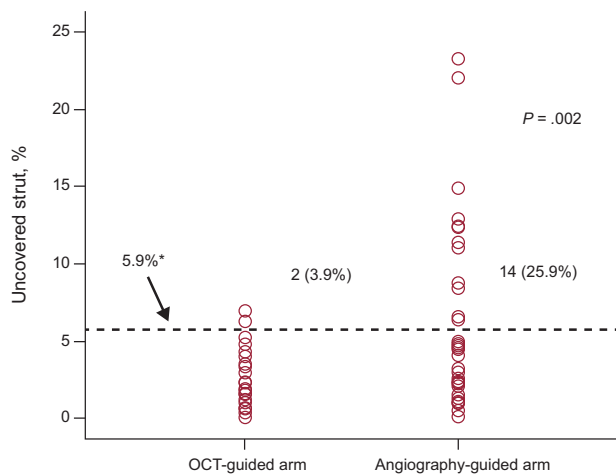


Figure 4. The incidence and severity of uncovered stent struts. The occurrence and severity of struts with unfavorable strut coverage ($\geq 5.9\%$) was significantly lower in optical coherence tomography guidance than angiography guidance. OCT, optical coherence tomography.

*The cutoff value of 5.9% is related with clinical outcomes based on previous study.⁹

lesions, small (< 2.5 mm) or large (> 4.0 mm) vessel diseases, left main diseases, chronic total occlusion, and bifurcation lesions—were specifically excluded. Therefore, we cannot speculate that the impact of OCT guidance would be greater in complex lesions and cannot recommend the use of OCT in every patient with simple lesions because its cost-effectiveness is not fully identified yet. Currently this is actively being investigated, but other previous studies have already suggested a potential clinical benefit of OCT-guided PCI.^{24,27} Third, we only used zotarolimus-eluting stents and a follow-up of 6 months; therefore, any extrapolation of our findings to other DES and longer follow-up durations should be done cautiously. Finally, although the sample size was adequate to assess the stent strut coverage using OCT at 6 months follow-up, it was too small to evaluate the long-term clinical outcomes of OCT-guided PCI.

CONCLUSIONS

Using a randomized, prospective study, we have shown that OCT-guided PCI of a DES resulted in significantly improved strut coverage and decreased malapposed struts at 6-month follow-up compared to conventional angiography guidance.

FUNDING

This study was supported by grants from the Korea Healthcare Technology R&D Project (Ministry for Health, Welfare and Family Affairs of the Republic of Korea) (A085012 and A102064), from the Korea Health 21 R&D Project (Ministry for Health, Welfare and Family Affairs of the Republic of Korea) (A085136), and the Cardiovascular Research Center from Seoul.

CONFLICTS OF INTEREST

None declared.

REFERENCES

- Farb A, Burke AP, Kolodgie FD, Virmani R. Pathological mechanisms of fatal late coronary stent thrombosis in humans. *Circulation*. 2003;108:1701–6.
- Finn AV, Joner M, Nakazawa G, Kolodgie F, Newell J, John MC, et al. Pathological correlates of late drug-eluting stent thrombosis: strut coverage as a marker of endothelialization. *Circulation*. 2007;115:2435–41.
- Tearney GJ, Regar E, Akasaka T, Adriaenssens T, Barlis P, Bezerra HG, et al. Consensus standards for acquisition, measurement, and reporting of intravascular optical coherence tomography studies: a report from the International Working Group for Intravascular Optical Coherence Tomography Standardization and Validation. *J Am Coll Cardiol*. 2012;59:1058–72.
- Ko YG, Kim DM, Cho JM, Choi SY, Yoon JH, Kim JS, et al. Optical coherence tomography findings of very late stent thrombosis after drug-eluting stent implantation. *Int J Cardiovasc Imaging*. 2012;28:715–23.
- Guagliumi G, Sirbu V, Musumeci G, Gerber R, Biondi-Zoccai G, Ikejima H, et al. Examination of the in vivo mechanisms of late drug-eluting stent thrombosis findings from optical coherence tomography and intravascular ultrasound imaging. *JACC Cardiovasc Interv*. 2012;5:12–20.
- Ozaki Y, Okumura M, Ismail TF, Naruse H, Hattori K, Kan S, et al. The fate of incomplete stent apposition with drug-eluting stents: an optical coherence tomography-based natural history study. *Eur Heart J*. 2010;31:1470–6.
- Kawamori H, Shite J, Shinke T, Otake H, Matsumoto D, Nakagawa M, et al. Natural consequence of post-intervention stent malapposition, thrombus, tissue prolapse, and dissection assessed by optical coherence tomography at mid-term follow-up. *Eur Heart J Cardiovasc Imaging*. 2013;14:865–75.
- Takano M, Inami S, Jang IK, Yamamoto M, Murakami D, Seimiya K, et al. Evaluation by optical coherence tomography of neointimal coverage of sirolimus-eluting stent three months after implantation. *Am J Cardiol*. 2007;99:1033–8.
- Won H, Shin DH, Kim BK, Mintz GS, Kim JS, Ko YG, et al. Optical coherence tomography derived cut-off value of uncovered stent struts to predict adverse clinical outcomes after drug-eluting stent implantation. *Int J Cardiovasc Imaging*. 2013;29:1255–63.
- Kim BK, Shin DH, Kim JS, Ko YG, Choi D, Jang Y, et al. Optical coherence tomography-based evaluation of malapposed strut coverage after drug-eluting stent implantation. *Int J Cardiovasc Imaging*. 2012;28:1887–94.
- Kume T, Akasaka T, Kawamoto T, Ogasawara Y, Watanabe N, Toyota E, et al. Assessment of coronary arterial thrombus by optical coherence tomography. *Am J Cardiol*. 2006;97:1713–7.
- Cutlip DE, Windecker S, Mehran R, Boam A, Cohen DJ, Van Es GA, et al. Clinical end points in coronary stent trials: a case for standardized definitions. *Circulation*. 2007;115:2344–51.
- Kim JS, Kim BK, Jang IK, Shin DH, Ko YG, Choi D, et al. Comparison of neointimal coverage between zotarolimus-eluting stent and everolimus-eluting stent using Optical Coherence Tomography (COVER OCT). *Am Heart J*. 2012;163:601–7.
- Kim S, Kim JS, Shin DH, Kim BK, Ko YG, Choi D, et al. Comparison of early strut coverage between zotarolimus- and everolimus-eluting stents using optical coherence tomography. *Am J Cardiol*. 2013;111:1–5.
- Mintz GS, Nissen SE, Anderson WD, Bailey SR, Erbel R, Fitzgerald PJ, et al. American College of Cardiology Clinical Expert Consensus Document on Standards for Acquisition, Measurement and Reporting of Intravascular Ultrasound Studies (IVUS). A report of the American College of Cardiology Task Force on Clinical Expert Consensus Documents. *J Am Coll Cardiol*. 2001;37:1478–92.
- Kim JS, Kang TS, Mintz GS, Park BE, Shin DH, Kim BK, et al. Randomized comparison of clinical outcomes between intravascular ultrasound and angiography-guided drug-eluting stent implantation for long coronary artery stenoses. *JACC Cardiovasc Interv*. 2013;6:369–76.
- Kim JS, Hong MK, Ko YG, Choi D, Yoon JH, Choi SH, et al. Impact of intravascular ultrasound guidance on long-term clinical outcomes in patients treated with drug-eluting stent for bifurcation lesions: data from a Korean multicenter bifurcation registry. *Am Heart J*. 2011;161:180–7.
- Park SJ, Kim YH, Park DW, Lee SW, Kim WJ, Suh J, et al.; MAIN-COMPARE Investigators. Impact of intravascular ultrasound guidance on long-term mortality in stenting for unprotected left main coronary artery stenosis. *Circ Cardiovasc Interv*. 2009;2:167–77.

19. Roy P, Steinberg DH, Sushinsky SJ, Okabe T, Pinto Slottow TL, Kaneshige K, et al. The potential clinical utility of intravascular ultrasound guidance in patients undergoing percutaneous coronary intervention with drug-eluting stents. *Eur Heart J.* 2008;29:1851–7.
20. Kim JS, Jang IK, Fan C, Kim TH, Kim JS, Park SM, et al. Evaluation in 3 months duration of neointimal coverage after zotarolimus-eluting stent implantation by optical coherence tomography: the ENDEAVOR OCT trial. *JACC Cardiovasc Interv.* 2009;2:1240–7.
21. Kim JS, Hong MK, Fan C, Kim TH, Shim JM, Park SM, et al. Intracoronary thrombus formation after drug-eluting stents implantation: optical coherence tomographic study. *Am Heart J.* 2010;159:278–83.
22. Takano M, Ohba T, Inami S, Seimiya K, Sakai S, Mizuno K. Angioscopic differences in neointimal coverage and in persistence of thrombus between sirolimus-eluting stents and bare metal stents after a 6-month implantation. *Eur Heart J.* 2006;27:2189–95.
23. Shin DH, Hong MK. Optimal duration of dual antiplatelet therapy after drug-eluting stent implantation. *Expert Rev Cardiovasc Ther.* 2012;10:1273–85.
24. Prati F, Di Vito L, Biondi-Zoccai G, Occhipinti M, La Manna A, Tamburino C, et al. Angiography alone versus angiography plus optical coherence tomography to guide decision-making during percutaneous coronary intervention: the Centro per la Lotta contro l'Infarto-Optimisation of Percutaneous Coronary Intervention (CLI-OPCI) study. *EuroIntervention.* 2012;8:823–9.
25. Ruiz-García J, Jiménez-Valero S, Galeote G, Sánchez-Recalde A, García-Blas S, Moreno R. Neoaterosclerosis como causa de reestenosis muy tardía de un *stent* convencional: evaluación mediante tomografía de coherencia óptica. *Rev Esp Cardiol.* 2013;66:403–5.
26. Ruiz-García J, Jiménez-Valero S, Sánchez-Recalde A, Galeote G, Carrizo S, Moreno R. Thrombosis del *stent* implantado en lesión ostial: diagnóstico y tratamiento guiados por tomografía de coherencia óptica. *Rev Esp Cardiol.* 2013;66:586–8.
27. Bezerra HG, Attizzani GF, Sirbu V, Musumeci G, Lortkipanidze N, Fujino Y, et al. Optical coherence tomography versus intravascular ultrasound to evaluate coronary artery disease and percutaneous coronary intervention. *JACC Cardiovasc Interv.* 2013;6:228–36.